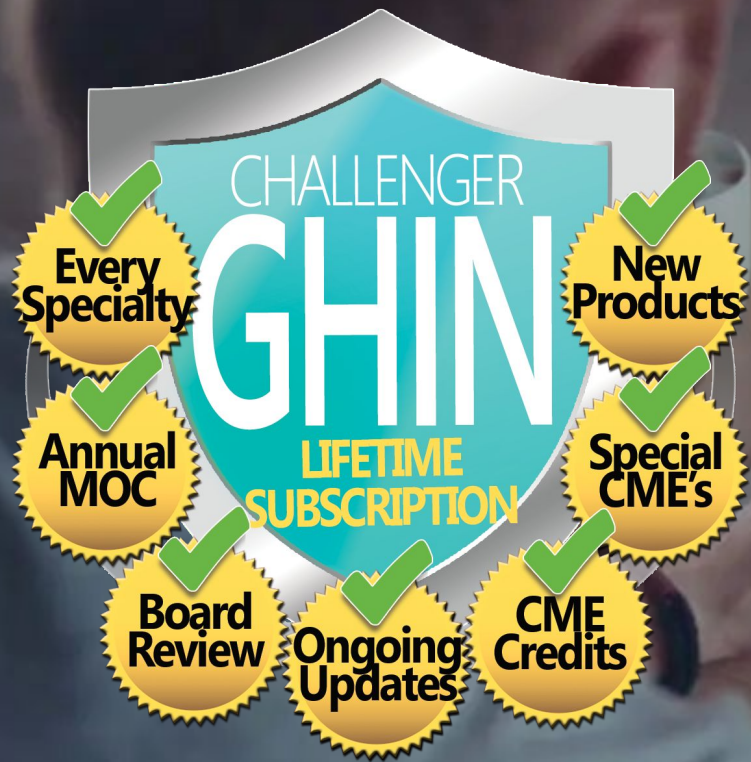




The Best for Life.  
Benefits of the  
**Challenger GHIN**  
Lifetime  
Subscription

  
**Full medical education library.**  
**Annual MOC requirements.**  
**Board exam review.**  
**Medical news, games & updates.**  
**Special CME requirements.**  
**Anytime CME credit fulfillment.**  
  
**Anywhere, anytime, any device.**  
**Free for life.**



# An everlasting career asset exclusively for GHIN Partners

- Career-required medical education content
- No more MOC exam or CME scrambles
- You stay informed and up-to-date
- No subscription fees. Free forever.
- Ongoing priority tech support
- Over \$15,000 in value





---

# A Leader in Medical Education for three decades.

Founded in 1991, Challenger Corporation ([challengercme.com](https://challengercme.com)) has been a pioneer and trusted expert in electronic medical education for thirty years.

Challenger serves all levels of practitioner across all major specialties including medical training programs and healthcare groups worldwide.

Y. I. I. Y. I.

**MEDCHALLENGER**

0

---


o  
  
+  
  
📁  
  
👤  
  
🛒  
  
🐾  
  
✖️  
  
☰  
  
●  
  
📺  
  
🔄  
  
🏆  
  
📦

## ASSESSMENT

**EM: Board Exam Simulator**

⏮
Pause
Score


A 71-year-old male with hypertension presents with chronic constipation. He denies any abdominal pain or weight loss. He smokes 20 cigarettes per day for the past 50 years. While performing a physical exam, you find no bowel movement and is now asymptomatic. A CT scan performed by a radiologist finds the patient in the bathroom and shows the following findings shown below.



A CT scan confirms the presence of a 4.1 cm suprarenal abdominal aortic aneurysm. What is the proper management of this patient?

|  |    | QUESTIONS |    |    |    |    |    |    |    |    |    |
|--|----|-----------|----|----|----|----|----|----|----|----|----|
|  |    | 1         | 2  | 3  | 4  | 5  | 6  | 7  | 8  | 9  | 10 |
|  | 11 | 12        | 13 | 14 | 15 | 16 | 17 | 18 | 19 | 20 | 21 |
|  | 22 | 23        | 24 | 25 | 26 | 27 | 28 | 29 | 30 | 31 | 32 |
|  | 33 | 34        | 35 | 36 | 37 | 38 | 39 | 40 | 41 | 42 | 43 |

■ Answered
 □ Current

A photograph of a middle-aged man with grey hair and a beard, wearing a white lab coat over a blue shirt. He is holding a tablet computer with both hands and looking down at the screen. A stethoscope is draped around his neck. The background is blurred, showing what appears to be a clinical setting.

---

**Earn CME Credit.  
Get info-rich Q&A.  
Print certificates.  
Done. Quick. Easy.  
Every year.**

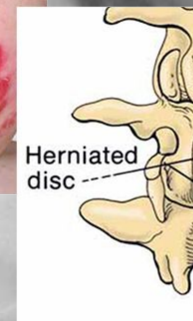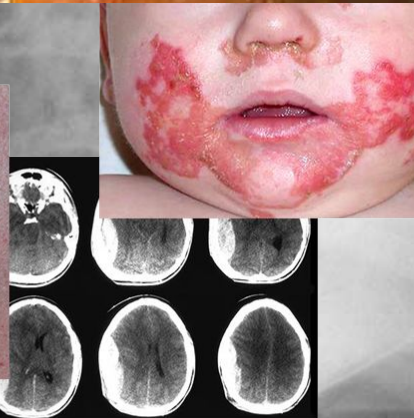
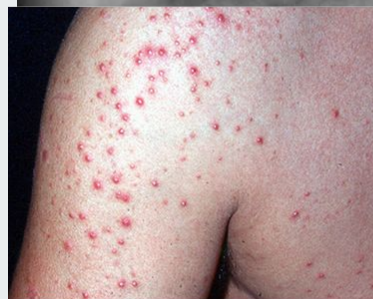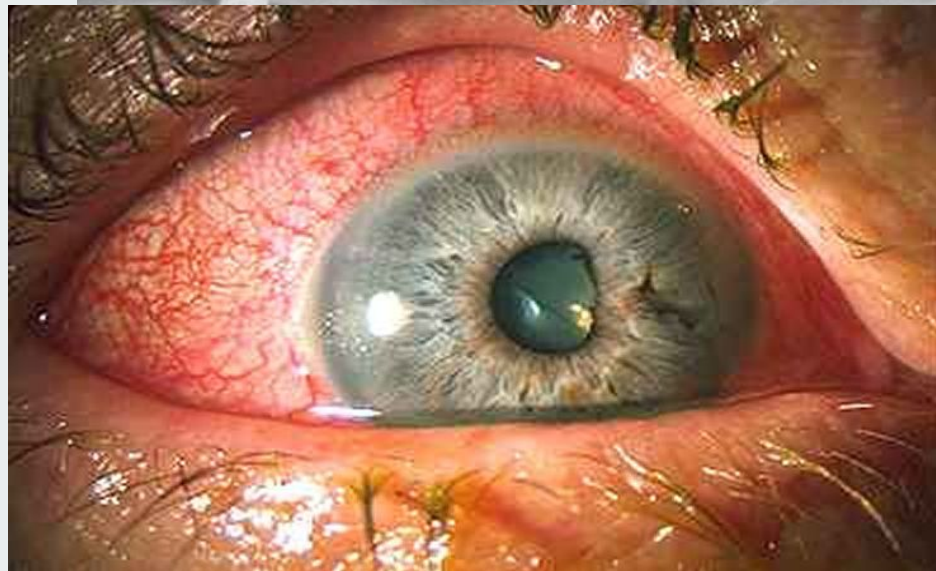Assets provide CME / CNE credits for all common MOC requirements including:

- AMA Category 1 CME Credit
- ANCC Contact Hour CEs
- State-required CME
- Annual MOC / CE requirements
- Specialty workplace CME requirements
- Specialty society CME
- OSHA / HIPAA

---

# Enjoy the Largest Media Library at your fingertips

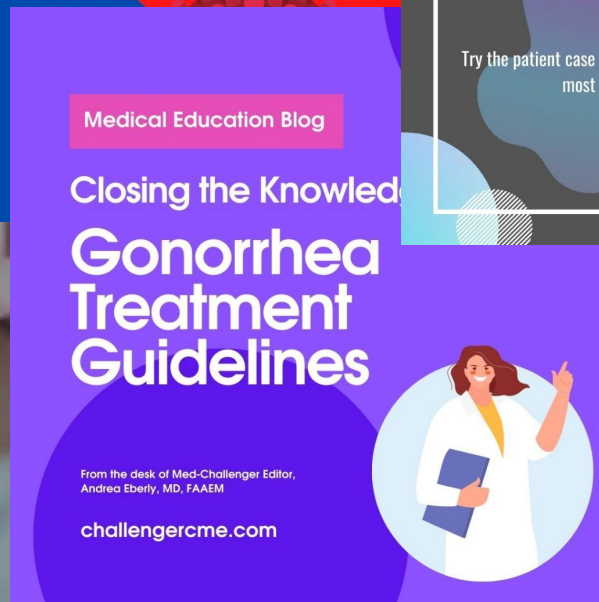
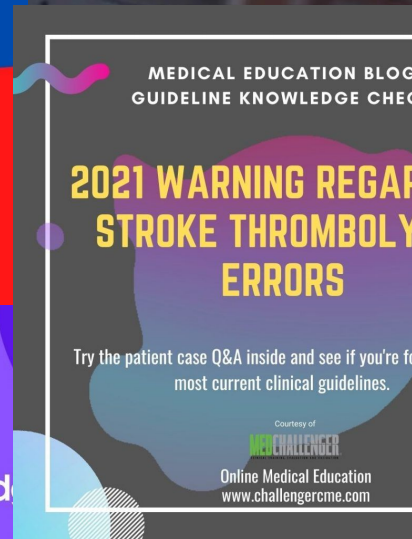
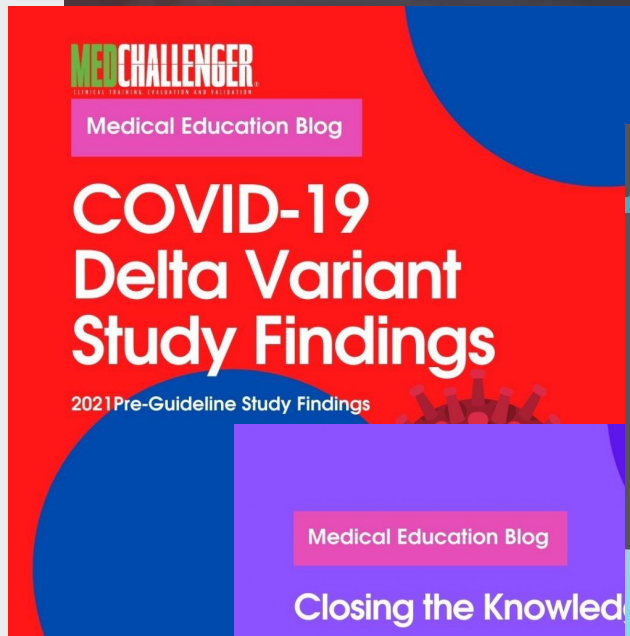
A wealth of high-resolution clinical media is integrated throughout the GHIN Lifetime Subscription and provides references for education and cited publication.





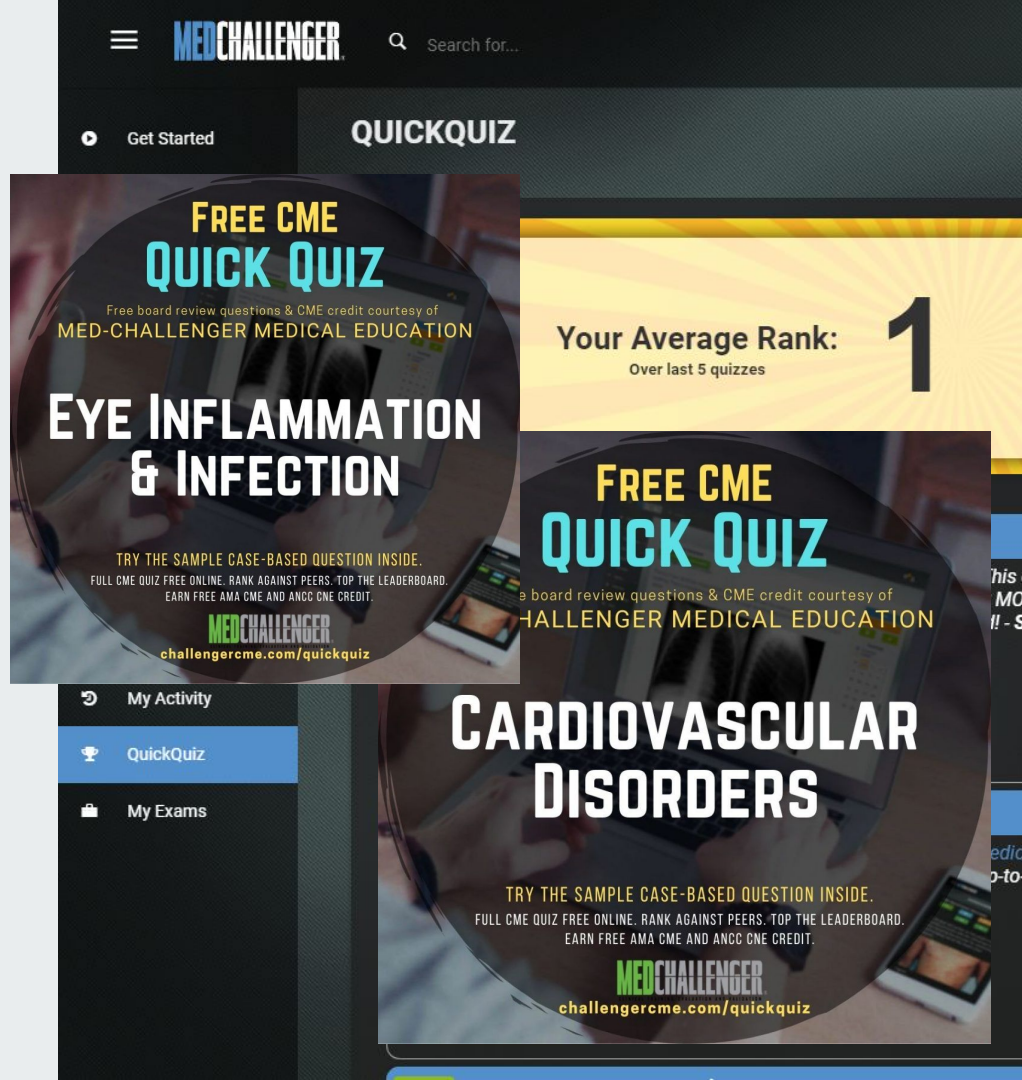
# Stay informed with Medical Education Case Blogs

Our medical education blog supplies you with a steady stream of guideline information and special Q&A cases written by our clinician authors.

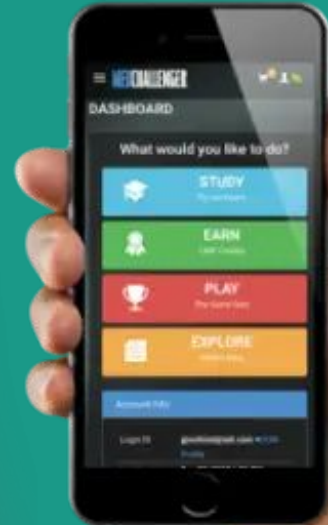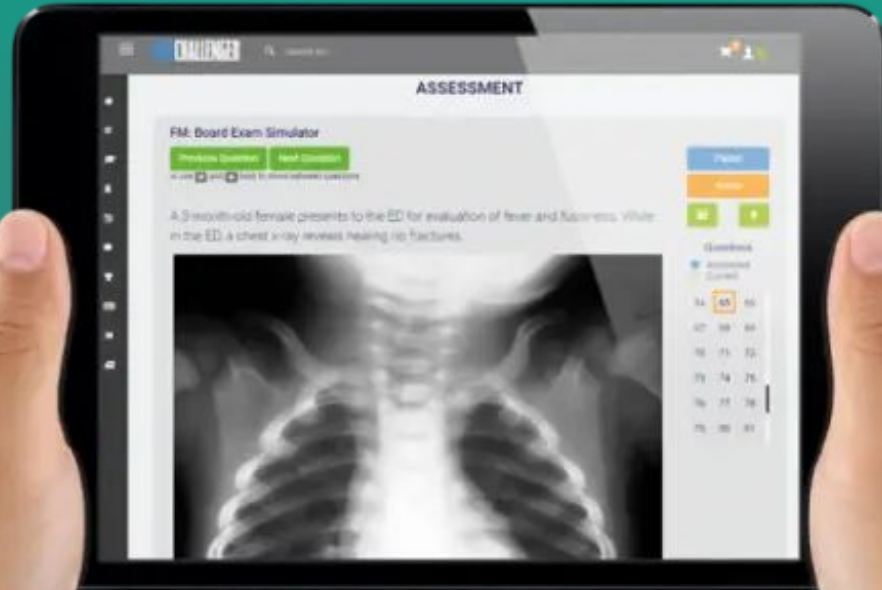


# Keep it fun with CME games and peer rankings

Our popular CME Quick Quiz issues a set of board review questions in a fun game-form where you can anonymously rank against peers and earn CME at the same time.



Everything is easy to use.  
Just click & get it done.



**Thank you.**



**[www.chall.com](http://www.chall.com)   [sales@chall.com](mailto:sales@chall.com)**